

FINAL ANSWER KEY

Question Paper Code:	105/2026/OL
Category Code:	895/2025, 899/2025
Exam:	Assistant Professor in Medical Gastroenterology
Date of Test	19-05-2026
Department	Medical Education

Question1:-Regarding Hyperemesis gravidarum, which is wrong?

- A:-It may lead onto hypokalemia
- B:-It may produce weight loss more than 5% of the prepregnancy weight
- C:-It may lead onto dehydration and ketosis
- D:-More common in multiparous mothers

Correct Answer:- Option-D

Question2:-Symptoms that suggest reflux induced asthma include all except

A:-Onset of wheezing in adulthood in the absence of a history of allergies or asthma, nocturnal cough or wheezing

- B:-Worsening of asthma in empty stomach, rest or in prone position
- C:-Asthma that is exacerbated by bronchodilators or glucocorticoid dependent
- D:-All of the above

Correct Answer:- Option-B

Question3:-Which of the following manifestations in HFE related Hemochromatosis will not be improving with phlebotomy?

- A:-Cardiac
- B:-Endocrinologic
- C:-Rheumatologic
- D:-Dermatologic

Correct Answer:- Option-C

Question4:-Gastric secretion of Ghrelin is stimulated by

A:-Neural (Vagusnerve)

B:-Mechanical (Distension)

C:-Hormonal (Glucagon)

D:-Chemical (Osmolarity, caloric content and macronutrient composition of meal)

Correct Answer:- Option-C

Question5:-Which of the following is not a component of Alvarado score for predicting acute appendicitis?

A:-Anorexia

B:-Tenderness in right lower quadrant

C:-Leukocytosis

D:-Red blood cells in urine

Correct Answer:- Option-D

Question6:-Which among the following is true regarding daily requirement of Magnesium by enteral route?

A:-100-200 mg

B:-200-300 mg

C:-300-400 mg

D:-400-500 mg

Correct Answer:- Option-C

Question7:-Regarding Acute Zinc toxicity in adults one among the following is not true?

A:-Epigastric pain, nausea and vomiting

B:-Diarrhoea

C:-Hyperpnoea, diaphoresis and weakness

D:-Constipation

Correct Answer:- Option-D

Question8:-Which of the following is not true regarding major cytokines that mediates hypercatabolism and hypermetabolism associated with metabolic stress?

A:-Interferon γ

B:-IL β

C:-IL5

D:-TNF α

Correct Answer:- Option-C

Question9:-Which among the following is a hormone is implicated in Late dumping syndrome?

A:-GLP1

B:-Enteroglucagon

C:-Peptide YY

D:-Vasoactive intestinal polypeptide

Correct Answer:- Option-A

Question10:-Vitamin B6 is predominantly absorbed from

A:-Stomach

B:-Duodenum

C:-Jejunum

D:-Ileum

Correct Answer:- Option-C

Question11:-Which of the following condition is not common in a child with Hirschsprung disease

A:-Meckel diverticulum

B:-Pyloric stenosis

C:-Tracheoesophageal fistula

D:-Small bowel atresia

Correct Answer:- Option-C

Question12:-In case of Viral hepatitis A, which of the following has the best sensitivity and specificity for predicting acute liver failure and mortality?

A:-Serum Creatinine level > 2mg/dl

B:-Total Bilirubin > 9.6 mg/dl

C:-INR > 1.40

D:-Serum Albumin < 2.5 mg/dl

Correct Answer:- Option-C

Question13:-Ferrochelatase enzyme defect produces

A:-Congenital erythropoietic porphyria

B:-Erythropoietic proto porphyria

C:-Hepatoerythropoietic porphyria

D:-Porphyria cutaneatarda

Correct Answer:- Option-B

Question14:-Regarding Abernethy malformation, which of the following is not true?

A:-Type I Abernethy malformation is more common in boys

B:-Type I Abernethy malformation is associated with congenital cardiac defects, biliary atresia and polysplenia

C:-Type I Abernethy malformation may associated with hypergalactosemia, hyperbilirubinemia or hyperammonemia

D:-In Type 2 Abernethy malformation Portal vein is intact

Correct Answer:- Option-A

Question15:-Which of the following is not a component of Enhanced Liver Fibrosis test?

A:-Tissue inhibitor of metalloproteinase I

B:-N-Terminal procollagen III peptide

C:-Hyaluronic acid

D:-Chondroitin sulphate

Correct Answer:- Option-D

Question16:-Which of the following quantitative liver function test is very useful for prediction of disease progression in HCV related chronic hepatitis?

A:-Lidocaine metabolite formation

B:-Aminopyrine breath test

C:-Galactose elimination capacity

D:-Caffeine clearance

Correct Answer:- Option-B

Question17:-Prevalence advanced liver fibrosis in type 2 diabetes mellitus is

A:-47-60%

B:-33-46%

C:-20-32%

D:-06-19%

Correct Answer:- Option-D

Question18:-Boyce sign may be elicited in which of the following condition?

A:-Duodenal diverticula

B:-Zenker diverticula

C:-Jejunal diverticula

D:-Colonic diverticula

Correct Answer:- Option-B

Question19:-Which of the following is not common with Anomalous pancreatico biliary union?

A:-Carcinoma gallbladder

B:-Adenomyomatosis gallbladder

C:-Carcinoma pancreas

D:-Bile duct carcinoma

Correct Answer:- Option-C

Question20:-Which of the following is true regarding Plain film in case of Acute mesenteric ischaemia?

A:-Thumb printing of the small bowel

B:-Pneumatosis linearis

C:-Portal or mesenteric vascular gas

D:-All of the above

Correct Answer:- Option-D

Question21:-Which of the following arteries is called the 'Lusorian artery'?

A:-Aberrant right subclavian artery

B:-Aberrant left subclavian artery

C:-Aberrant common carotid artery

D:-Bovine arch

Correct Answer:- Option-A

Question22:-Which of the following is the most common type of esophageal atresia?

A:-Isolated esophageal atresia

B:-Esophageal atresia and the distal segment forming tracheoesophageal fistula

C:-Esophageal atresia and the proximal segment forming tracheoesophageal fistula

D:-H-type fistula

Correct Answer:- Option-B

Question23:-Which one of the following is false about Deglutitive inhibition?

A:-It is absent in pseudo achalasia

B:-It is a cardinal feature of peristaltic mechanism

C:-Results from hyperpolarisation of circular smooth muscles

D:-Mediated by cholinergic neurons in myenteric plexus

Correct Answer:- Option-D

Question24:-Which one of the following is false about Transient lower esophageal sphincter relaxations (tLESR)?

A:-Lasts for more than 10 seconds

B:-Tension receptors are more involved

C:-The neurotransmitter involved is GABA

D:-It is not always associated with Gastroesophageal reflux disease

Correct Answer:- Option-B

Question25:-Which of the following is false regarding cervical inlet patch?

A:-Found in 25% of patients during upper endoscopy

B:-Can harbour Helicobacter pylori

C:-Has a possible association with globus pharyngeus

D:-Has a statistically significant association with proximal esophageal adenocarcinoma

Correct Answer:- Option-A

Question26:-Which of the following is a risk factor for esophageal adenocarcinoma?

A:-Human Papilloma Virus

B:-Achalasia cardia

C:-Tylosis

D:-Obesity

Correct Answer:- Option-D

Question27:-'Boyce sign' is seen in which of the following?

A:-Trachea-esophageal fistula

B:-Zenker's diverticula

C:-Esophageal atresia

D:-Esophageal webs

Correct Answer:- Option-B

Question28:-Which of the following is true regarding Granular cell tumor of esophagus?

A:-Most common location is proximal esophagus

B:-Malignant transformation is frequent

C:-S100 positive

D:-PAS positive and diastase sensitive

Correct Answer:- Option-C

Question29:-Which of the following is not true about Lymphocytic esophagitis?

A:-Commonly seen in 5th to 7th decade age group

B:-At least 10 intraepithelial lymphocytes per high power field must be present for diagnosis

C:-Dysphagia is a common symptom

D:-Female preponderance

Correct Answer:- Option-B

Question30:-The screening for Barrett's esophagus should be considered in chronic GERD patients with the following risk factors except

A:-Esophageal adenocarcinoma in a first degree relative

B:-Tobacco smoking

C:-Alcohol consumption

D:- Obesity

Correct Answer:- Option-C

Question31:-Which of the following is not a definite risk factor for gastric adenocarcinoma?

A:-Chronic atrophic gastritis

B:-Ebstein-Barr virus

C:-History of Billroth-II surgery

D:-History of gastric ulcer

Correct Answer:- Option-D

Question32:-Which of the following is a strong risk factor for stress-related gastric and duodenal mucosal injury?

A:-ICU patient with burns

B:-Coronary artery disease

C:-Uncontrolled Diabetes mellitus

D:-Chronic kidney disease

Correct Answer:- Option-A

Question33:-The interstitial cells of Cajal (ICCs) are known to originate from which of the following cell types?

A:-Neural crest-derived cells

B:-Smooth muscle cells

C:-c-Kit-positive mesenchymal cell precursors

D:-Hematopoietic stem cells

Correct Answer:- Option-C

Question34:-Which one of the following is false about migrating motor complex?

A:-Occurs in fasting state

B:-Originate in stomach and terminate in rectum

C:-Occurs once in 90 to 120 minutes

D:-It occurs normally after vagotomy

Correct Answer:- Option-B

Question35:-One of the following is true regarding Environmental metaplastic atrophic gastritis

A:-Low serum Pepsinogen 1

B:-Hypergastrinemia

C:-Antral involvement

D:-Anti intrinsic factor and parietal cell positive

Correct Answer:- Option-C

Question36:-Which of the following is false regarding Menetrier's disease?

A:-It will have an aggressive course in the post-partum period

B:-Associated with Cytomegalovirus infection

C:-Enhanced Epidermal growth factor signalling in gastric mucosa

D:-Associated with protein losing enteropathy

Correct Answer:- Option-A

Question37:-Which of the following criteria is not recommended for gastric Endoscopic mucosal resection?

A:-The cancer is in the mucosa and the lymph nodes are not involved, as indicated by EUS examination

B:-The maximum size of the tumor is less than 4 cm when the lesion is slightly elevated (type IIa) and more than 1 cm when the tumor is flat or slightly depressed (type IIb or IIc) without an ulcer scar

C:-There is no evidence of multiple gastric cancers or simultaneous abdominal cancers

D:-The cancer is of the intestinal type

Correct Answer:- Option-B

Question38:-One of the following is false regarding Gastric volvulus?

A:-Defect in diaphragmatic hiatus increases risk of gastric volvulus

B:-Unable to pass nasogastric tube into stomach

C:-Mesentero-axial type is most common

D:-Emergency endoscopic reduction can be tried in acute gastric volvulus

Correct Answer:- Option-C

Question39:-As per the Forrest classification of endoscopic appearance of bleeding gastric ulcer, which of the following type denotes 'non-bleeding visible vessel'?

A:-Type 1A

B:-Type 1B

C:-Type 2A

D:-Type 2B

Correct Answer:- Option-C

Question40:-The following is true regarding Zollinger Ellison syndrome

A:-Ectopic gastric release by Gastrinomas

B:-30% of Gastrinomas are found in the Gastrinoma triangle

C:-Can be associated with MEN1 syndrome

D:-Increased basal acid output

Correct Answer:- Option-B

Question41:-The anatomical abnormality in Incomplete type Pancreas Divisum is?

A:-Complete failure of fusion between dorsal and ventral ducts

B:-Absence of the ventral duct

C:-Dorsal and ventral ducts having a small communication

D:-None of the above

Correct Answer:- Option-C

Question42:-False statement regarding Pancreatobiliary malunion (PBM) is?

A:-It is most frequently associated with gall bladder neoplasm

B:-In the Y type of PBM, there is a long common channel more than 20 mm

C:-Choledochal cysts are very frequently associated with PBM

D:-Biliary reflux into the pancreas increases the risk of acute pancreatitis

Correct Answer:- Option-B

Question43:-All are true about the common histology in Type 2 Autoimmune pancreatitis except

A:-Idiopathic duct centric pancreatitis

B:-Granulocytic epithelial lesion

C:-Neutrophilic infiltration with microabscesses

D:-Obliterative phlebitis

Correct Answer:- Option-D

Question44:-In ERCP, if the main pancreatic duct appears abnormal with 4 abnormal side branches but there are no large cavities, obstruction, strictures or filling defects, the Cambridge grading of Chronic Pancreatitis is

A:-Equivocal

B:-Mild

C:-Moderate

D:-Severe

Correct Answer:- Option-C

Question45:-Regarding pain management in Chronic Pancreatitis (CP), which statement is false?

A:-Delivering lipases to the duodenum or very proximal jejunum is primarily responsible for reduction of pancreatic secretion

B:-Protease destroys CCK releasing factor and helps in analgesia

C:-Non enteric coated pancreatic enzyme supplements need concomitant use of Proton pump inhibitors

D:-In advanced CP, PERT is less effective in managing pain

Correct Answer:- Option-A

Question46:-A 42-year-old woman presents with abdominal discomfort and a palpable epigastric mass. There is a well encapsulated solid lesion with cystic components of size 7 cm in pancreatic body in the CECT. EUS shows internal hemorrhage and cystic degeneration. It was later diagnosed to be a solid pseudopapillary neoplasm (SPN). What is the typical pathological hallmark of a resected SPN?

A:-Papillary tumor within the pancreatic duct with surrounding lakes of mucin

B:-Uniform neoplastic cells with nuclear grooves, separated by vascular hyalinized stroma

C:-Small cells in nests with round nuclei having salt and pepper chromatin

D:-Granulocytic epithelial lesion

Correct Answer:- Option-B

Question47:-After the landmark WATERFALL trial, the current guidelines recommend fluid resuscitation in Acute pancreatitis as

A:-3-5 ml/kg/hr

B:-5-10 ml/kg/hr

C:-10-15 ml/kg/hr

D:-15-20 ml/kg/hr

Correct Answer:- Option-B

Question48:-All are associated with pancreatic Neuroendocrine tumors except

A:-Neurofibromatosis-1

B:-VonHippel Lindau syndrome

C:-Tuberous sclerosis

D:-Lifraumeni syndrome

Correct Answer:- Option-D

Question49:-Type 3 c diabetes has all except

A:-Low glucagon levels

B:-Frequent treatment induced hypoglycemia

C:-Fewer microvascular complications than Type 1 DM

D:-Overall lesser risk of ketosis

Correct Answer:- Option-C

Question50:-In an incidentally detected pancreatic cyst, all are included in the "GREY ZONE OF RISK" except

A:-IPMN cyst size 30-40 mm

B:-Main duct diameter 5-10 mm

C:-Enhancing mural nodule less than 5 mm

D:-Increase in size during follow up

Correct Answer:- Option-C

Question51:-The characteristic mutation in syndromic paucity of interlobular bile ducts presenting as chronic cholestasis in children is

A:-NOTCH 2

B:-JAG 1

C:-PKHD 1

D:-FIC 1

Correct Answer:- Option-B

Question52:-A 55 yr old woman was incidentally detected to have several GB calculi with extensive intramural calcification of the GB wall. The most appropriate next step is

A:-EUS for GB wall thickness

B:-MRCP for CBD stones

C:-Observation

D:-Panning cholecystectomy

Correct Answer:- Option-D

Question53:-Which of the following is a risk factor for cholangiocarcinoma?

A:-Caucasian ethnicity

B:-Cirrhosis

C:-PBC

D:-Chronic Hepatitis E

Correct Answer:- Option-B

Question54:-Identify the false statement

A:-PSC may be diagnosed even after total proctocolectomy for Ulcerative colitis

B:-Purely small bowel Crohn's disease has more risk of PSC than colonic Crohn's

C:-PSC patients have higher risk of pouchitis after Ileal pouch Anal anastomosis

D:-Crohn's Disease associated with PSC is not typically associated with strictures or fistulae

Correct Answer:- Option-B

Question55:-Distal bile duct stricture, papillitis and acalculous cholecystitis are the typical cholangiographic features in?

A:-Caustic cholangitis

B:-PSC

C:-Portal cavernoma Cholangiopathy

D:-Ischemic cholangiopathy

Correct Answer:- Option-D

Question56:-All are prognostic models for PSC except

A:-Amsterdam-Oxford model

B:-Anali score

C:-District score

D:-Lemann index

Correct Answer:- Option-D

Question57:-According to the TNM and AJCC/UICC staging for Carcinoma GB, Stage T1b tumor needs re-exploration and assessment for resectability. Invasion of which layer is T1b?

A:-Lamina propria

B:-Submucosa

C:-Muscularis mucosa

D:-Muscularis propria

Correct Answer:- Option-D

Question58:-After a laparoscopic cholecystectomy for acute cholecystitis, a 40 year old lady developed abdominal pain and bile draining from surgical drain. CT abdomen showed no collections. ERCP demonstrated low grade bile leak from duct of Luschke with no filling defects in biliary tree. Next best step is?

A:-Conservative management with prophylactic antibiotics

B:-ERCP + Plastic stent

C:-Nasobiliary drain

D:-Laparoscopic repair

Correct Answer:- Option-B

Question59:-In a patient with PFIC and elevated GGT levels, the mutated protein is

A:-FIC 1

B:- BSEP

C:-MDR3

D:-MRP2

Correct Answer:- Option-C

Question60:-Which is the false statement regarding Total Parenteral Nutrition and Gall stones?

A:-TPN is associated with both cholelithiasis and acalculous cholecystitis

B:-There is preferential flow of bile into GB due to Sphincter of Oddi failure to relax

C:-CCK Octapeptide should not be routinely used in long term TPN patients

D:-After 3-4 months of TPN, 40% patients develop gallstones

Correct Answer:- Option-C

Question61:-Which is false regarding Abernethy malformation?

A:-In Type 1a malformation there is complete absence of portal vein

B:-Type 1 shunt occurs more often in girls than in boys

C:-Type 2 malformation is associated with cardiac defects and biliary atresia

D:-Type 1 malformation maybe complicated by the formation of Focal Nodular Hyperplasia

Correct Answer:- Option-C

Question62:-Which of the following statements is correct regarding the liver?

A:-Liver receives 70% of blood supply from portal vein and 30% from hepatic artery

B:-Liver receives 60% of blood supply from Portal vein and 40% from hepatic artery

C:-Liver receives 80% oxygen from Portal vein and 20% from Hepatic artery

D:-Liver receives 70% oxygen from Portal vein and 30% from Hepatic artery

Correct Answer:- Option-A

Question63:-Which of the following statements is false regarding Kupffer cells?

A:-Kupffer cells are specialized tissue macrophages

B:-They have an abundance of lysosomes, micropinocytic vesicles and fuzzy coated vacuoles

C:-They possess sieve plates

D:-They are derived from bone marrow stem cells or monocytes

Correct Answer:- Option-C

Question64:-Which of the statements is false regarding Alkaline Phosphatase?

A:-Isoenzymes are produced from bone, liver, intestine, placenta and kidney

B:-Clearance of ALP from serum is dependent on the biliary tract patency and liver functional capacity

C:-Patients with O and B blood groups can have elevated ALP after a fatty meal

D:-A low serum ALP level may occur in Acute Liver failure due to Wilson disease

Correct Answer:- Option-B

Question65:-Cholestatic Hepatitis is caused by all the following drugs except

A:-ACE inhibitors

B:-Amoxicillin Clavulanic acid

C:-Chlorpromazine

D:-Carbamazepine

Correct Answer:- Option-D

Question66:-Which of the following is true regarding PBC?

A:-The frequency of AMA in PBC patients is 70-75%

B:-AMA appears to be cytotoxic in PBC

C:-Failure to respond to UDCA is associated with a reduced transplant free survival and increased risk of disease related complications

D:-Patients with AMA negative PBC tends to have worse clinical course and therapeutic response to UDCA

Correct Answer:- Option-C

Question67:-Which of the following is the mechanism of action of Saroglitazar in NASH pharmacotherapy?

A:-Dual PPAR α and γ agonist

B:-PPAR γ antagonist

C:-FXR agonist

D:-Dual PPAR α and δ agonist

Correct Answer:- Option-A

Question68:-Which of the following is false regarding PTLD (Past Transplantation Lymphoproliferative Disorder) following liver transplantation?

A:-Caused by uncontrolled B cell proliferation in response to primary EBV infection

B:-Pediatric recipients are at decreased risk for PTLD

C:-Intensive immunosuppression with OKT3 increases PTLD risk post liver transplantation

D:-Chronic graft rejection is seen in increased frequency in survivors of PTLD

Correct Answer:- Option-B

Question69:-Which is false regarding Hepatopulmonary Syndrome (HPS)?

A:-A pulse oximetry value of less than 96% detects all patients with PaO₂ less than 70%.

B:-ExtraMELD points may be allocated to a patient with HPS

C:-In contrast echocardiography, detection of contrast in the left side of the heart within 1-3 cardiac cycles after its appearance in the right atrium indicates intrapulmonary shunting

D:-The lesser degree of preoperative hypoxemia and adequate correction with 100% oxygen are predictors of potential reversibility of HPS after Liver Transplantation

Correct Answer:- Option-C

Question70:-Which of the following statements is true regarding amebic liver abscess?

A:-Amebic liver abscess is less likely than pyogenic liver abscess to have an acute presentation

B:-Jaundice is uncommon in amebic liver abscess and signifies a poor prognosis

C:-

It is 10 times as common in women than in men

D:-40-50% patients report an antecedent history of bloody diarrhoea with amebic dysentery

Correct Answer:- Option-B

Question71:-An obese male patient 47 years of age is diagnosed with chronic hepatitis C infection. All the factors can be associated with progression of fibrosis in him except

A:-Obesity

B:-Male gender

C:-Age

D:-Viral genotype

Correct Answer:- Option-D

Question72:-Which of the following scenario carries high risk of HBV reactivation in an HBsAg positive patient?

A:- Antirejection regimen for solid organ transplant

B:-Immunosuppressive therapy with Azathioprine

C:-5mg Prednisolone for 2 weeks

D:-Hematopoietic stem cell transplantation

Correct Answer:- Option-D

Question73:-Which is a false statement regarding Wilson disease?

A:-Neurologic presentation occurs in the second or third decades of life or later

B:-Seizures and intellectual impairment is common in Wilson disease

C:-Most of the patients with neuropsychiatric presentation has KF ring

D:-KF rings and sunflower cataract disappear with chelation therapy

Correct Answer:- Option-B

Question74:-All are associated with high SAAG ascites except

A:-Myxoedema

B:-Fatty liver of pregnancy

C:-Postoperative lymphatic leak

D:-ALF

Correct Answer:- Option-C

Question75:-All are true of alcohol associated liver diseases except

A:-Classic histologic features of alcohol associated hepatitis include Mallory Denk bodies and ballooning degeneration of hepatocytes

B:- Serum AST level <400 U/L ratio of AST/ALT >2 is characteristic of alcoholic hepatitis

C:-Alcohol associated cirrhosis is typically micronodular or mixed micro and macronodular

D:-Chronic alcoholics are less susceptible to acetaminophen hepatotoxicity

Correct Answer:- Option-D

Question76:-Congenital anomalies associated with Congenital Anorectal malformations include all except

A:-Atrial septal defect

B:-Tracheo Esophageal fistula

C:-Trisomy 21

D:-Cleft palate

Correct Answer:- Option-B

Question77:-Which of the following statements about small intestinal motility is false?

A:-Phasic contractions in the small intestine generally last from 0.8 to 6.0 seconds

B:-The slow wave in the small intestine is generated by the Interstitial Cells of Cajal

C:-Ascending excitation refers to the contraction that occurs distal to a stimulus

D:-The propagation of contractions along the small intestine is determined by the propagation velocity of the slow wave

Correct Answer:- Option-C

Question78:-The Neuroendocrine cell types in the small intestine and their products are given in the following table. All are matched correctly except

Cell Type Cell product

I P/D1 Ghrelin

II EC 5 HT

III G Gastrin

IV M Neurotensin

A:-I

B:-II

C:-III

D:-IV

Correct Answer:- Option-D

Question79:-In the treatment of IBS which of the following statements are correct

- i. Abdomen pain is related to defaecation
- ii. IBS Diarrhoea is Bristol stool types 4 and 5
- iii. Serine proteases have a role.
- iv. Chloride channel activators have a role in treatment of IBS-D

A:-All of the above

B:-i and iii

C:-iii and iv

D:-ii and iv

Correct Answer:- Option-B

Question80:-A 55 year old comes to the casualty with features of acute abdominal pain and vomiting. Plain XRay abdomen showed multiple air fluid levels. CT Abdomen was ordered to rule out Intestinal obstruction. You expect to find all the following findings except

A:-Beak sign

B:-Target sign

C:-Pneumatosis Intestinalis Linearis

D:-Mercedes sign

Correct Answer:- Option-D

Question81:-In patients with Imerslund-Gräsbeck disease, which of the following molecular components is primarily affected, leading to cobalamin malabsorption?

A:-Amnionless gene mutations

B:-Thyroid hormone receptors

C:-Cubilin enzyme deficiency

D:-IF-Cbl receptor down regulation

Correct Answer:- Option-A

Question82:-The role of colon in malabsorption is as follows. Which of the following statements is false?

A:-The rate limiting step in the conversion of polysaccharides to short chain fatty acids is the conversion of monosaccharides to short chain fatty acids

B:-In normal subjects more than 80 g of carbohydrates much reach the colon to cause diarrhoea

C:-90% of short chain fatty acids are absorbed by the colonic mucosa

D:-If colonic gas volumes are high, the volume of intra colonic gas absorbed can decrease to 20%

Correct Answer:- Option-B

Question83:-A middle aged female Diabetic patient presents to the OPD with chronic symptoms of flatulence, diarrhoea, bloating. Her routine evaluation including blood tests, stool test, Imaging studies and upper GI and Lower GI studies were negative. For further evaluation of SIBO the following statements are correct except

A:-Rifaximin can be effective in the treatment

B:-Breath test using Lactulose and Hydrogen will be useful

C:-Glucose Hydrogen breath test rise by more than 10 ppm at 90 minutes is diagnostic with a sensitivity of 62.5% and specificity of 81.8%

D:-Exocrine pancreatic insufficiency should be ruled out

Correct Answer:- Option-C

Question84:-A patient with Post traumatic abdomen who underwent multiple intestinal resections who is on TPN presents with Jaundice, abdominal distension and altered sensorium. His Hb is 11 g/dL, WBC 5000 /ml, Platelet 80000/ml, Total Bilirubin 10 mg/dL, ALT 55 U/L, Serum Creatinine 1.7 mg/dL, INR 1.8. The treatment options for include

A:-Small bowel transplantation

B:-Combined liver and small bowel transplant

C:-Continue TPN

D:-GLP-2 analogue

Correct Answer:- Option-B

Question85:-A 42 year old male migrant labourer from North India presents with a history of chronic diarrhoea. He was symptom free after he avoided wheat in the diet. He has recurrence of symptoms with abdominal pain, bloating and diarrhoea. All of the following statements are true in this situation except

A:-Histology can be false negative on Gluten free diet

B:-HLA-DQ2/DQ8 confirms the diagnosis of celiac disease

C:-Celiac disease affects mucosa

D:-Rice, Corn and millets do not activate celiac disease

Correct Answer:- Option-B

Question86:-A 38-year-old male agricultural worker from a rural village in Kerala, India presents with a 2-year history of chronic, watery diarrhea, fatigue, and weight loss. He denies any recent travel outside of Kerala. He consumes a traditional Kerala diet rich in rice, lentils, and fish. On physical examination, he appears malnourished with mild abdominal distention. Lab tests reveal microcytic anemia, iron deficiency, and low vitamin B12 levels. Anti-tissue transglutaminase antibody (TTG) and deamidated gliadin peptide (DGP) are negative. Upper endoscopy with duodenal biopsies shows villous atrophy.

Considering the clinical scenario and investigative findings, which of the following statements is most likely incorrect?

A:-Tropical sprue is a possible diagnosis in this case, despite the negative serology for celiac disease

B:-Villous atrophy is complete in Tropical sprue unlike Celiac disease

C:-Folate and vitamin B12 supplementation are essential for addressing the nutritional deficiencies

D:-Atrophic Gastritis is seen in 50% of patients with Tropical Sprue

Correct Answer:- Option-B

Question87:-A 70 year old male presenting with diarrhoea and fever. Diarrhoea, abdominal pain and vomiting for 3 weeks. Watery diarrhoea with low volume stools with stool frequency 3 to 4 per day. No similar illness in family or neighbourhood. History of Diabetes Mellitus and Lymphoma. Vital signs shows tachycardia, hypotension and elevated temperature. Right iliac fossa tenderness. CT scan shows mild wall thickening of terminal ileum. Normal colonoscopy. Colonic biopsy was normal. Stool culture negative. Gram negative rods seen on blood culture. The following is the possible etiological agent.

A:-Salmonella enterica

B:-Vibrio Cholerae

C:-Enteroinvasive E.Coli

D:-Yersenia Enterocolitica

Correct Answer:- Option-D

Question88:-A 72-year-old woman with a history of heart failure and chronic obstructive pulmonary disease (COPD) is admitted for acute exacerbation of COPD requiring mechanical ventilation. She receives broad-spectrum antibiotics for suspected hospital-

acquired pneumonia. On day 4 of hospitalization, she develops new-onset watery diarrhea with a frequency of 10 times per day. Suspected Clostridium Difficile infection. Which of the statements regarding management is correct

A:-Oral Metronidazole is the preferred treatment

B:-Enzyme Linked Immunoassay for GDH toxin has got 85% sensitivity

C:-Antimotility agents should be used

D:-Surgical consultation should be sought early

Correct Answer:- Option-B

Question89:-A 32-year-old street vendor presents with a 2-day history of profuse watery diarrhea (up to 15 times daily) and forceful vomiting. He denies fever, abdominal pain, or recent travel. He acknowledges consuming street food from vendors near a crowded market with questionable sanitation. On examination, he appears dehydrated with dry mucous membranes and weak pulses.

Laboratory investigations reveal : Hyponatremia (serum sodium 130 mEq/L), Metabolic alkalosis, Microscopic examination of stool reveals gram negative, comma-shaped bacilli. Which of the following is not corrects?

A:-Antimicrobial therapy is not recommended

B:-IV Fluids with electrolytes in isotonic concentrations

C:-Zinc supplementation may be useful

D:-Confirmation requires stool culture

Correct Answer:- Option-A

Question90:-The composition of WHO(2002) ORS solution for carbohydrates (g/L)/ Sodium (mmol/l)/Potassium(mmol/L)/Chloride (mmol/L) is as follows

A:-20/90/20/65

B:-13.5/75/20/65

C:-30/50/25/45

D:-25/45/20/35

Correct Answer:- Option-B

Question91:-Which of the following statements is/are correct about appetite?

- i. Ghrelin administration stimulates food intake
- ii. Semaglutide is a dual GLP-1 receptor agonist/glucose-dependent insulinotropic polypeptide (GIP) receptor agonist
- iii. Tirzepatide is more efficacious in inducing weight loss than semaglutide

A:-Only i

B:-Only i and ii

C:-Only i and iii

D:-All of the above

Correct Answer:- Option-C

Question92:-Which of the following statements is/are correct about hepatitis D virus (HDV)?

- i. HDV has a single-stranded circular RNA genome.
- ii. Bulevirtide inhibits the entry of HDV into hepatocytes by binding to sodium taurocholate cotransport polypeptide (NTCP) and has shown positive results in treatment of HDV infection
- iii. Lonafarnib is an inhibitor of assembly and release of HDV from infected hepatocytes

A:-Only i

B:-Only i and ii

C:-only i and iii

D:-All of the above

Correct Answer:- Option-D

Question93:-Which of the following statements is/are correct about diagnosis and treatment of acute appendicitis?

- i. For its diagnosis, ultrasound (US) is preferred over computed tomography (CT) in children and pregnant women, whereas CT is preferred in adults.
- ii. Clinical trials have shown that more than half the patients with acute appendicitis treated with antibiotics alone never need surgery during long-term follow-up.
- iii. Appendiceal or cecal cancer may be present in around 20% of patients older than 60 years who present with acute appendicitis.

A:-Only i

B:-Only i and ii

C:-Only iii

D:-All of the above

Correct Answer:- Option-D

Question94:-Which of the following statements is/are correct about treatment of inflammatory bowel disease?

- i. Vedolizumab is a humanized IgG 1 monoclonal antibody to $\alpha 4\beta 7$ integrin expressed on the surface of B and T cells.
- ii. Ustekinumab is a fully human IgG1 monoclonal antibody directed against the p19 subunit of IL-23. but not that of IL-12.
- iii. Biologic agents should not be used in pregnant women with inflammatory bowel disease because of increased risk of poor fetal outcomes.

A:-Only i

B:-Only i and ii

C:-Only iii

D:-All of the above

Correct Answer:- Option-A

Question95:-Which of the following statements is/are correct about celiac disease?

- i. Nearly one-third of persons who have HLA- DQ2 develop celiac disease.
- ii. Presence of antibodies against deamidated gliadin peptide (DGP) is more specific than that of anti-gliadin antibodies for the diagnosis of this disease.
- iii. Scalloping of duodenal folds is a fairly specific feature of celiac disease.

A:-Only i

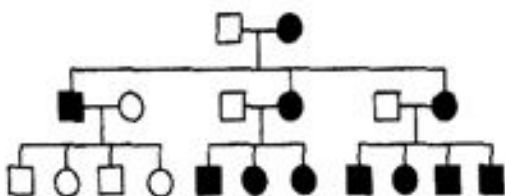
B:-Only ii

C:-Only ii and iii

D:-All of the above

Correct Answer:- Option-B

Question96:-In a family, several members have a neurological disease. The family tree is shown below.



Which of the following modes of inheritance are possible with this family tree?

- i. Autosomal dominant inheritance
- ii. Autosomal recessive inheritance
- iii. Mitochondrial inheritance

A:-Only i and ii

B:-Only i and iii

C:-Only ii and iii

D:-all of the above

Correct Answer:- Option-B

Question97:-As per international recommendations, which of the following is the best method for screening children born to HCV-infected women for HCV:

A:-Using anti-HCV antibody test soon after birth

B:-Using HCV RNA test soon after birth

C:-Using anti-HCV antibody test at or after 18 months of age

D:-Using HCV RNA test at or after 18 months of age

Correct Answer:- Option-C

Question98:-Which of the following statements are correct about Genome-Wide Association Studies (GWAS)?

- i. These involve testing for millions of genetic variants in DNA samples from persons with and without the disease of interest
- ii. These studies are useful since only a few subjects in each group are needed.
- iii. The association identified in such studies are highly likely to imply causation.

A:-Only i

B:-Only ii

C:-Only i and ii

D:-All of the above

Correct Answer:- Option-A

Question99:-Which of the following statements are correct about narrow-band imaging?

- i. This technique involves the use of light of blue and red colour during endoscopy to enhance certain aspects of mucosal surface.
- ii. The coloured light is absorbed by hemoglobin and hence blood vessels appear dark whereas the other tissues reflect light and appear as illuminated.
- iii. Light of shorter wavelength penetrates only the shorter layer and shows details of the mucosal surface, whereas light of the longer wavelength penetrates deeper and shows details of deeper tissues.

A:-Only i and ii

B:-Only ii and iii

C:-Only i and iii

D:-All of the above

Correct Answer:- Option-B

Question100:-Which of the following statements are correct about the use of artificial intelligence (AI) in medicine?

- i. AI tools can identify patterns in images and hence perform well in classifying radiologic, pathology and endoscopy images.
- ii. An important advantage of AI is that a tool developed in one setting can be applied to other settings quickly and with good results.
- iii. AI tools can sometimes hallucinate, i.e. provide an output not based on facts, but is fabricated and distorted.

A:-only i and ii

B:-only ii and iii

C:-only i and iii

D:-all of the above

Correct Answer:- Option-C